



## MLH1 and MSH2 gene mutation patterns in Lynch syndrome-associated colorectal cancer in Sudan

Balgis Elhag Ibrahim Tager<sup>1</sup>, Salah Eldin G. Elzaki<sup>2</sup>, and Ahmed Abdula Agabeldour<sup>3</sup>

<sup>1</sup>Department of Histopathology and Cytology, Faculty of Medical Laboratory Sciences, West Kordofan University, Elnuhood, Sudan.

<sup>2</sup>Department of molecular epidemiology, Tropical Medicine Research Institute, National Centre for Research Khartoum Sudan.

<sup>3</sup>Department of Pathology, Faculty of Medicine, Kordofan University, El-Obeid, Sudan.

### ABSTRACT

**Background:** Colorectal cancer (CRC) is increasingly becoming dominant in Sudan, which is attributed to several factors, including hereditary mutations in the DNA mismatch repair genes MLH1 and MSH2. Therefore, this study aimed to examine the MLH1 and MSH2 gene mutation patterns in Lynch syndrome-associated colorectal cancer in a series of Sudanese patients with CRC. **Methodology:** This study investigated 50 patients with CRC who attended El-Obeid Hospital during the period from 2017 to 2022. The presence of MLH1 and MSH2 was indicated by immunohistochemical testing of formalin-fixed, paraffin-wax-embedded tissues. **Results:** The MLH1 mutation was positive in 28% of the study population and negative in 72% of them. The MSH2 mutation was positive in 42% and negative in 58% of the study subjects. The MLH1 and MSH2 mutations shared positivity in 18% and negativity in 24% of the cases. **Conclusion:** According to the present studies, CRC is more prevalent in women. LS is more common in Sudanese patients with CRC than in many other reports throughout the world. MSH2 mutations are more prevalent in Sudanese patients than MLH1 mutations.

**Keywords:** colorectal cancer, Lynch syndrome, MLH1, MSH2, Sudan.

**Correspondence to:** Balgis Elhag Ibrahim Tager, Email: [bintelhag@yahoo.com](mailto:bintelhag@yahoo.com)

**Cite this article:** Tager BEI, Elzaki SGE<sup>2</sup>, and Agabeldour AA. Medical Research Updates 2024;1(2): 23-28. DOI: 0000

### INTRODUCTION

Lynch syndrome (LS), formerly known as hereditary non-polyposis colorectal cancer (HNPCC), is an autosomal dominant illness characterized by mutations in the DNA mismatch repair genes MLH1, MSH2, MSH6, and PMS2. LS predisposes to a wide range of malignancies, the most common of which are colorectal tumors. The key risk factors for LS include gender, age, and the genes implicated [1]. Autoimmunity and immunodeficiency aid in the development of malignancies in LS [2]. More than 90% of CRC cases are adenocarcinomas in glandular epithelial cells of the large intestine (colon and rectum), with the remaining 5% being hereditary nonpolyposis CRC (HNPCC) or familial adenomatous polyposis (FAP) caused by APC, MLH1, and MSH2 mutations [3, 4]. DNA mismatch repair (MMR) gene homozygous and heterozygous germline mutations are the cause of Lynch syndrome. MSH2 accounts for about 40–50%, MLH1 (30–37%), and MSH6 mutations are detected in 7–13% and up to 9 percent of PMS2 cases. Patients with LS have a lifetime chance of acquiring colorectal cancer of 50–80% [5]. Mismatch repair (MMR) proteins (MLH1, PMS2,

MSH2, and MSH6) are the major DNA repair system that repair mismatches and small insertions and deletions that occur during cellular replication; their deficiency (MMR-D) affects microsatellites and causes alterations known as microsatellite instability (MSI), as well as loss of MMR protein expression in tumors. CRC is generally sporadic, with approximately 5% to 10% being hereditary colon cancer syndromes, which include Lynch syndrome, adenomatous polyposis syndromes, and hamartomatous polyposis syndromes. [6]. Colorectal cancer (CRC) is one of the most frequent malignancies globally; approximately 20–30% of CRCs are familial, and LS is the most common form of hereditary CRC caused by germline mismatch repair (MMR) gene mutations (MLH1, MSH2, MSH6, or PMS2) [5]. However, there is a scarcity of data from Sudan on colorectal cancer epidemiology. As a result, the purpose of this study was to look at the MLH1 and MSH2 gene mutation patterns in Lynch syndrome-associated colorectal cancer in a series of Sudanese patients with CRC.



### **MATERIALS AND METHODS**

This study used 50 tissue blocks obtained from histopathology facilities in El-Obeid, Northern Kordofan State. Formalin-fixed wax-embedded tissue blocks were acquired from CRC patients who had surgical resections. All of the tissues were formalin-fixed and wax-embedded. The sample consisted of all CRC patients revealed to histopathology laboratories in El-Obeid between 2017 and 2022. For the purpose of diagnosis, conventional histology was used to make the main diagnosis of CRC. In each case, a consultant histopathologist confirmed the diagnosis of CRC. Following that, immunohistochemistry methods were used to detect two MMR proteins (MLH1 and MSH2). Immunohistochemical testing was carried out using two monoclonal antibodies (MLH1: monoclonal mouse anti-human ki67, clone MIB-1, and MSH2: monoclonal mouse anti-human VEGF.) as follows: Two formalin-fixed, paraffin-embedded tumor slices (3m) were cut and mounted on salinized slides (Dako). Following xylene deparaffinization, slides were rehydrated in a graded series of alcohol before being placed in running water. Then, using a PT connection, antigen retrieval for MLH1 and MSH2 was performed. Endogenous peroxidase activity was stopped for 10 minutes with 3% hydrogen peroxidase and methanol, followed by 20 minutes at room temperature in a moisture chamber with 100–200 l of primary antibodies, followed by a washing in phosphate buffered saline. The MLH1 and MSH2 primary antibodies were ready for use (Dako, Carpintera). After three minutes of washing with PBS, the Dako-EnVision™ Flex kit incubated dextran-labeled polymer for 20 minutes to detect antibody binding. Finally, the sections were washed three times in PBS before being stained

with 3 diaminobenzidine tetra hydrochloride (DAB) (Dako) for up to 5 minutes to produce the distinctive brown stain for the observation of the antibody/enzyme combination. Hematoxylin was then used to stain the slides. Positive and negative control slides are also generated for each staining session. The positive control slides included the antigen under research, while the negative control slides were made from the same tissue block but treated with PBS rather than the primary antibody. An investigator evaluated each slide, and a consultant histopathologist validated and rated the results.

### **Ethical Considerations**

Beside obtaining ethical acceptance from relevant authorized bodies, The Human Research Ethics Committee (HREC) at the Prof. Medical Research Consultancy Center has approved the research protocol. HREC 0001/MRCC.12/23).

### **Statistical Analysis**

The Statistical Package for the Social Sciences (SPSS) version 23 was used for the statistical analyses. Descriptive data reported as frequencies and percentages were included in the statistical analysis.

### **RESULTS**

Of the 50 patients, 23 (46%) were males and 27 (54%) were females, aged 20 to 75 years, with a mean age of 48. Most patients were aged 41–60 years, followed by 61–75 and ≤ 40 years, representing 23/50 (46%), 11 (22%), and 8 (16%), respectively, as shown in Fig 1. The MLH1 mutation was positive in 14 (28%) of the study population and negative in 36 (72% of them). The MSH2 mutation was positive in 21 (42%), and negative in 29 (58%), of the study subjects. The MLH1 and MSH2 mutations shared positivity in 9 (18%) and negativity in 12 (24% of the cases), as seen in Fig 2.

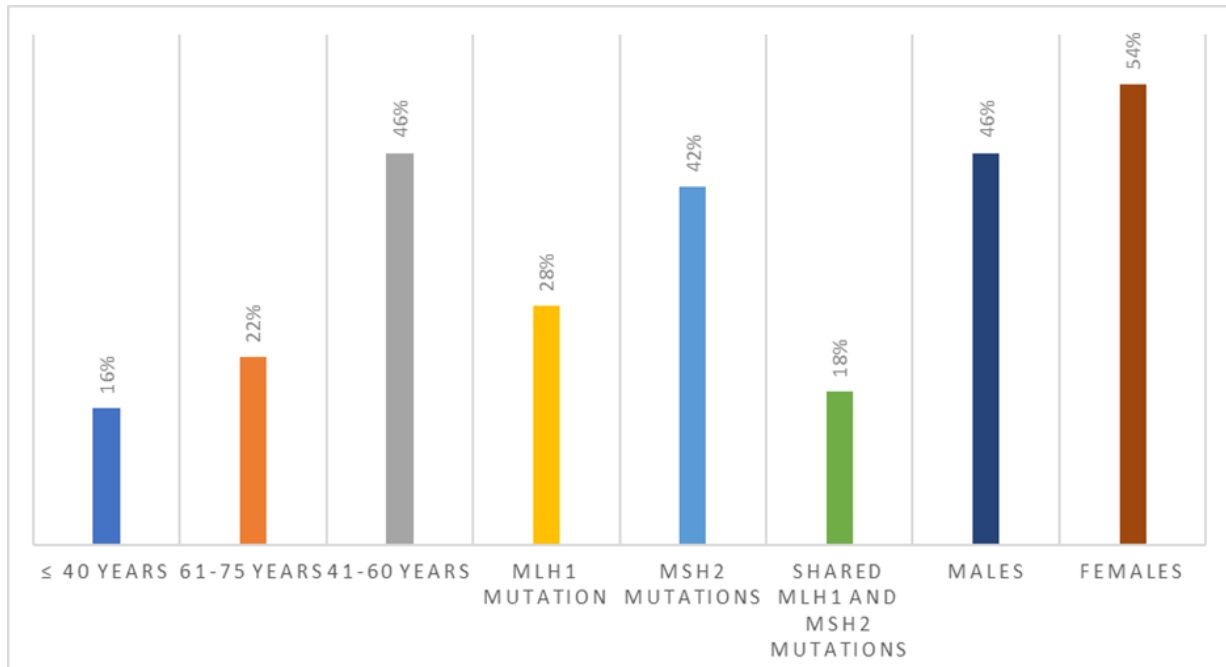


Figure 1. Description of the study subjects by age and mutation status.

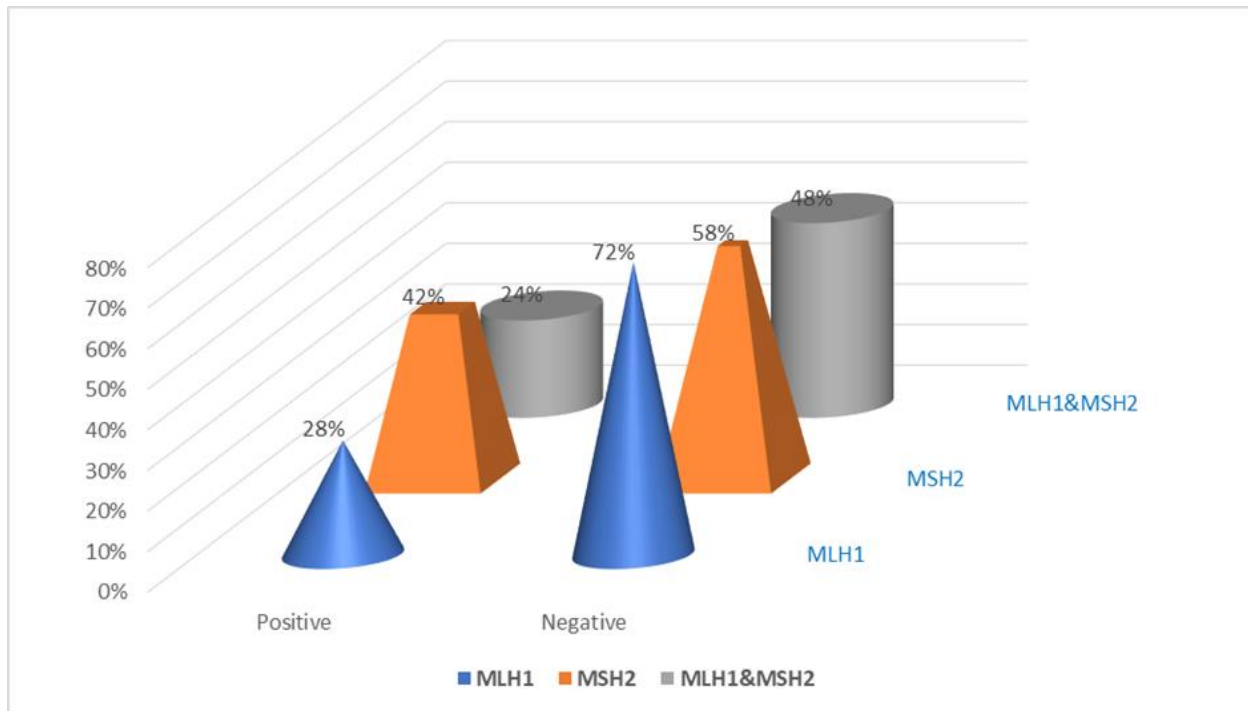


Figure 2. Description of the study subjects by MLH1 and MSH2 mutation status.

## DISCUSSION

LS is one of the most common hereditary cancer syndromes in humans, affecting around 3% of colorectal cancer patients who are not chosen, as well as 10%–15% of persons who have mismatch

repair (MMR) genes, including MLH1, MSH2, MSH6, and PMS2 [6, 7]. The reason we looked into MLH1 and MSH2 mutations in a group of Sudanese patients with CRC was because pathogenic germline variants in the MLH1, MSH2, and MSH6



genes are thought to cause most LS cases [8]. MSH2 (42% of the mutations found in this study), MLH1 (28%), and shared mutations in 24% of the subjects. Despite the fact that there is a scarcity of data on the subject in Sudan, some studies have revealed lower prevalence rates than ours. In a Sudanese study, immunohistochemistry was employed to determine the BRAF (V600E) mutant status and mismatch repair (MMR) status. A mismatch repair deficient (dMMR) subtype was discovered in 16% of instances, and Lynch syndrome (LS) was suspected in up to 14% of patients [9]. The family traditions in North Sudan are well-known for the practice of consanguineous marriage. Certain Sudanese ethnic groups are known to practice consanguinity and within-group marriage, which are major contributors to the community's elevated burden of genetic disease [10]. In the current investigation, we noticed that females were more frequently affected by CRC than males. However, it has already been suggested that patients with Lynch syndrome have a lifetime risk of colorectal cancer (CRC) of 24-52%, which is higher in males (28-75%) than in females (24-72%). There is a clear genotype-phenotype relationship, especially in the case of MSH6 mutations. With an MSH6 mutation, men have a 54% lifetime risk, while women have a 30% risk [11]. There is a significant association ( $p < 0.001$ ) between the MSH6 mutation and female gender and gynecological malignancies. Male MSH2 and MLH1 carriers have higher rates of prostate, upper GI tract, biliary, or pancreatic cancers compared to the general population, whereas female carriers have higher rates of endometrial and ovarian malignancies [12]. In conclusion, according to the present studies, CRC is more prevalent in women. LS is more common in Sudanese patients with CRC than in many other reports throughout the world. MSH2 mutations are more prevalent in Sudanese patients than MLH1 mutations.

### Acknowledgment:

The authors would like to express their gratitude to people at different histopathology laboratories in El-Obeid city for their kind cooperation.

### Authors contribution

**BE:** Conceptual, consultation, funding, and approval of the final version.

**SG:** Conceptual, data analysis, funding, and approval of the final version.

**AAA:** Conceptual, manuscript drafting, and approval of the final version.

**Funding:** Self-funded.

**Data availability:** The data presented in this study are available on request to the corresponding author.

**Disclosure of interest:** No interest to declare.

### References:

- 1-Galuppini F, Fassan M, Mastracci L, et al. The histomorphological and molecular landscape of colorectal adenomas and serrated lesions. *Pathologica* 2021; 113(3):218-229.
- 2- Cerretelli G, Ager A, Arends MJ, Frayling IM. Molecular pathology of Lynch syndrome. *Journal of Pathology* 2020; 250(5):518-531.
- 3-Ahmad R, Singh J K, Wunnava A, Al-Obeid O, Abdulla M, and Srivastava KS. Emerging trends in colorectal cancer: dysregulated signaling pathways (review) *International Journal of Molecular Medicine* 2021; 47(3): 14.
- 4-Yamashita K, Fukushima H, Teramoto M, Okita K, Ishikawa A, Sakurai A, Akagi K, and Nakase H. Interval between the First Cancer and the Genetic Diagnosis in Lynch Syndrome Probands. *Intern Med* 2021;60(17):2719-2724.
- 5-Kim H, Lim KY, Park JW, et al. Sporadic and Lynch syndrome-associated mismatch repair-deficient brain tumors. *Lab Invest.* 2022;102(2):160-171.
- 6- Peltomäki P, Nyström M, Mecklin JP, Seppälä TT. Lynch syndrome genetics and clinical implications *Gastroenterology.* 2023;164(5):783-799. doi: 10.1053/j.gastro.2022.08.058.
- 7- Bolivar AM, Duzagac F, Sinha KM, Vilar E. Advances in vaccine development for cancer prevention and treatment in Lynch syndrome *Mol Aspects Med.* 2023;93:101204. doi: 10.1016/j.mam.2023.101204.
- 8- Sleiman J, Farha N, Beard J, Bena J, Morrison S, Milicia S, Heald B, Kalady MF, Church J, Liska D, Mankaney G, Burke CA. Incidence and prevalence of advanced colorectal neoplasia in Lynch syndrome. *Gastrointest Endosc.* 2023 Sep;98(3):412-419.e8. doi: 10.1016/j.gie.2023.04.001.
- 9- Elsayed I, Geraghty R, Mekki SO, et al. Evaluating the utility and feasibility of mismatch repair testing



for colorectal cancer patients in a low- to middle-income country. *Sci Rep.* 2022 Jun 29;12(1):10998. doi: 10.1038/s41598-022-14644-6.

10- Hamad RS, Ibrahim ME. CMMRD is caused by the PMS1 mutation in a Sudanese consanguineous family. *Hered Cancer Clin Pract* 20, 16 (2022). <https://doi.org/10.1186/s13053-022-00222-4>.

11-Schneider R, Schneider C, Jakobeit C, Fürst A, Möslein G. Gender-Specific Aspects of Lynch Syndrome and Familial Adenomatous Polyposis. *Viszeralmedizin.* 2014 Apr;30(2):82-8. doi: 10.1159/000360839.

12- Cerrato C, Pandolfo SD, Autorino R, Panunzio A, Tafuri A, Porcaro AB, Veccia A, De Marco V, Cerruto MA, Antonelli A, Derweesh IH, and Maresma MCM. Gender-specific counseling for patients with upper tract urothelial carcinoma and Lynch syndrome. *World J. Urol.* 2023 Jul;41(7):1741-1749. doi: 10.1007/s00345-023-04344-9.