



## Histopathological characteristics of cervical cancer in El-Obeid tertiary hospitals: A 5-year retrospective study

Salma Suleiman Hassan<sup>1</sup>, Ahmed Abdallah Agebeldour<sup>1,2</sup>, Hussain Gadelkarim Ahmed<sup>3,4</sup>.

<sup>1</sup>Kordufan Histopathology center, El-Obeid, NK, Sudan.

<sup>2</sup>Department of pathology, faculty of medicine, University of Kordofan, NK, Sudan.

<sup>3</sup>Prof Medical Research Consultancy Center, El-Obeid, NK, Sudan.

<sup>4</sup>Department of histopathology and cytology, FMLS, University of Khartoum, Sudan.

### Abstract

**Background:** Lack of cervical screening programs makes cervical cancer a major health issue in underdeveloped countries. Early clinical symptoms beyond the disease's histological profile are crucial for preventing fatal consequences and providing appropriate treatment. **Methodology:** This study is a retrospective descriptive analysis of cervical cancer cases recorded in El-Obeid, North Kordofan, spanning from January 2019 to April 2024. **Results:** We reviewed 190 cervical cancer reports. Patients suffered 72% vaginal bleeding, 26% discharge, and a few urinary symptoms. The mass's gross morphology showed 54% exophytic growth and 32% infiltrative growth. In the cervical cancer study, 74% were SCC and 26% were adenocarcinoma. Big cell non-keratinizing squamous cell carcinomas (SCC) made up 58% of them and were moderately differentiated (grade II). Additionally, 25% were grade I keratinizing SCC. FIGO staging placed 90% of patients at stage 1. **Conclusion:** among Sudan, uterine cervix cancer is still common among patients seeking medical attention for various complaints. Moderately differentiated SCC was most prevalent. Since cervical cancer is generally preventable in its premalignant state, early diagnosis and screening policies should be implemented.

**Keywords:** Squamous cell carcinoma, large cell non keratinizing, North Kordofan

**Correspondence to:** Dr. Salma Suleiman Hassan. <sup>1</sup>Kordufan Histopathology center, El-Obeid, NK, Sudan. Email: [salmasuliman51@gmail.com](mailto:salmasuliman51@gmail.com)

**Cite this article:** Hassan, et al. Medical Research Updates Journal 2024;2(2): 55- 63. DOI:<https://doi.org/10.70084/pmrc.mruj2.22>

### Introduction

Cervical cancer continues to be a significant health issue, ranking as the fourth most prevalent cancer among women worldwide. In 2022, there were approximately 660,000 new cases and 350,000 deaths attributed to this disease [1]. It is also one of the most prevalent gynecological malignancies in underdeveloped nations, as the majority of cervical cancer cases occur in low-socioeconomic areas where screening programs are not well-established [2].

Conversely, it is the second most prevalent fatal tumors in underdeveloped nations and the tenth in industrialized countries [3]. Research has shown that the majority of women who acquired cervical cancer were infected with one or more subtypes of the human papillomavirus (HPV), particularly types 16 and 18. Various risk factors for HPV infection have been taken into account, including engaging in sexual activity with new male partners and having many male partners. Additionally, several other risk factors have been identified as potential triggers for HPV,



including immunosuppression (after transplant surgery), HIV infection, tobacco usage, and the use of combination oral contraceptives [5].

A set of clinical characteristics, including atypical vaginal bleeding (such as bleeding between periods, after sexual intercourse, or after menopause), foul-smelling vaginal discharge, pelvic pain, and weight loss, have been identified as warning signs for cervical cancer [6].

Cervical cancer is classified into two types based on the specific cells in which it originates: Squamous cell carcinoma, which is the most common malignant lesion observed during histological investigation, and Adenocarcinoma, which is less prevalent [7]. Our study focused on finding various histopathological characteristics of cervical cancer and their connection with age.

### Materials and methods

This study was a retrospective descriptive analysis conducted in two prominent institutes that provide histopathology services in the northern region of Kordofan state: Kordofan Histopathology Center and El-Obeid International Hospital. All histopathology reports from January 2019 to April 2024 were collected and analyzed.

### Statistical analysis

All acquired the demographic data, clinical information, and histopathological data were collected and organized into a data sheet. This data was then loaded into the SPSS program version 24 and Microsoft Excel 2016 for

analysis. Frequencies, charts, and cross tabs were generated from the analysis.

### Ethical consideration

Permission to retrieve the samples was granted by the officials at both the Kordofan Histopathology Center and El-Obeid International Hospital.

### Ethical Approval

The protocol of this study was approved from the human ethics committee at Prof Medical Research Consultancy Center.

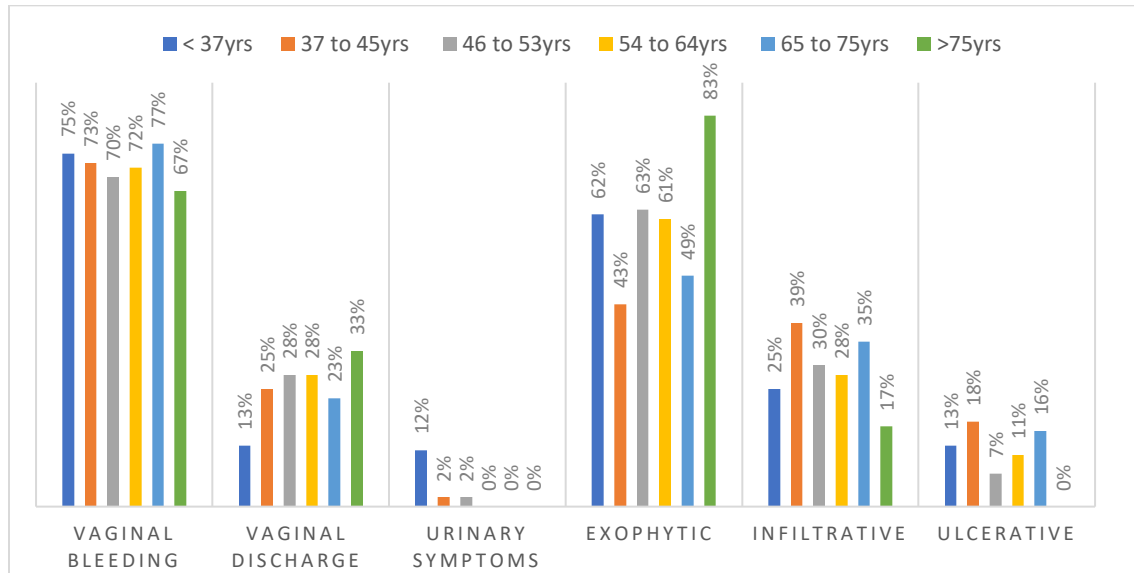
### Results

This study examined a total of 190 patients diagnosed with cervical cancer. The participants' age range was between 30 and 90 years, with a mean age of  $55 \pm 13.5$  years. Most patients were between the ages of 54 and 64, accounting for 46 out of 190 (24%). The next most common age group was 37 to 45 years, with 44 out of 190 patients (23%). The next two age groups, 45 to 53 years and 65 to 75 years, each accounted for 43 out of 190 patients, representing 22% of the total. When examining the symptoms reported by the patients, the most common complaint was vaginal bleeding, followed by vaginal discharge and urinary symptoms. These symptoms accounted for 138 out of 190 cases (72%), 49 cases (25%), and 3 cases (1.6%), respectively. The mass that could be seen most often had an exophytic shape, followed by infiltrative and ulcerative shapes, which made up 105 of the 190 cases (54%), 32%, and 12%, respectively.



**Table 1. Distribution by age, clinical presentation, and macroscopic morphology**

<b>Variable</b>	<b>&lt; 37 years</b>	<b>37 - 45</b>	<b>46 - 53</b>	<b>54-64</b>	<b>65-75</b>	<b>&gt;75yrs</b>	<b>Total</b>
<b>Age</b>							
Vaginal bleeding	6	32	30	33	33	4	138
Vaginal discharge	1	11	12	13	10	2	49
Urinary symptoms	1	1	1	0	0	0	3
<b>Total</b>	<b>8</b>	<b>44</b>	<b>43</b>	<b>46</b>	<b>43</b>	<b>6</b>	<b>190</b>
<b>Macroscopic morphology</b>							
Exophytic	5	19	27	28	21	5	105
Infiltrative	2	17	13	13	15	1	61
Ulcerative	1	8	3	5	7	0	24
<b>Total</b>	<b>8</b>	<b>44</b>	<b>43</b>	<b>46</b>	<b>43</b>	<b>6</b>	<b>190</b>



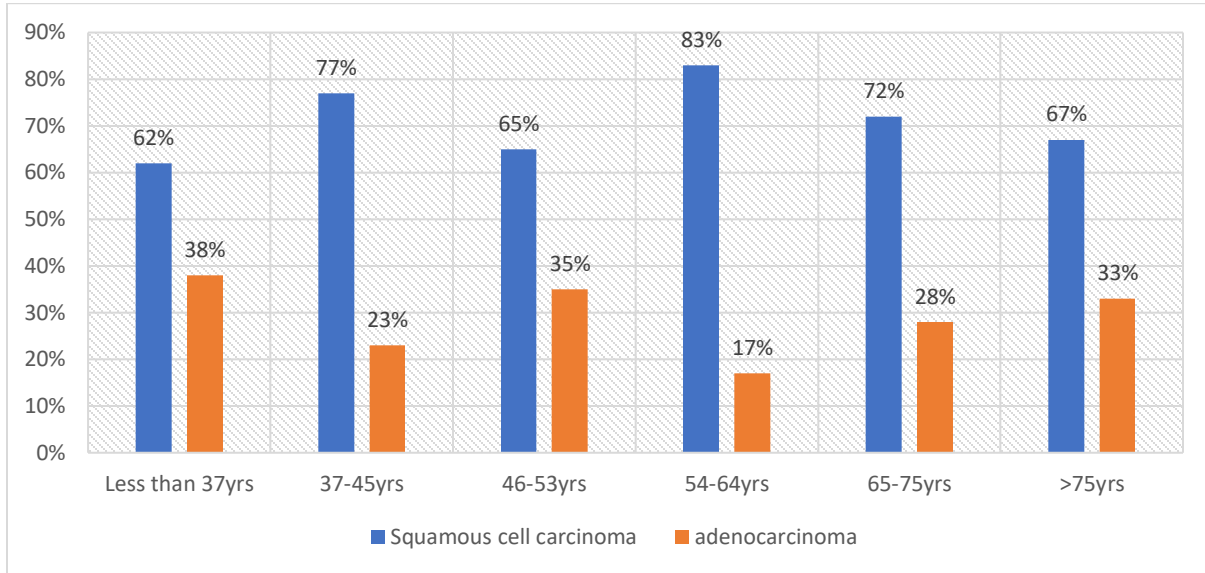
**Figure 1. Description by age the clinical presentation and the macroscopic morphology (gross appearance).**

The most prevalent tumor type seen was squamous cell carcinoma (SCC) with a frequency of 140 out of 190 cases (74%). Adenocarcinoma accounted for 50 out of 190 cases (26%). Among SCC patients, the highest number belonged to the age group of 54-64 years, followed by the age groups of 37-45 years and 65-80 years, representing 38 out of

140 cases (27%), 34 out of 140 cases (24%), and 31 out of 140 cases (22%), respectively. The majority of patients with adenocarcinoma were in the age category of 46-53 years, accounting for 15 out of 50 cases (30%). This was followed by the age group of 65-75 years, which had 12 cases (24%).

**Table 2. Distribution by age group, major tumor category**

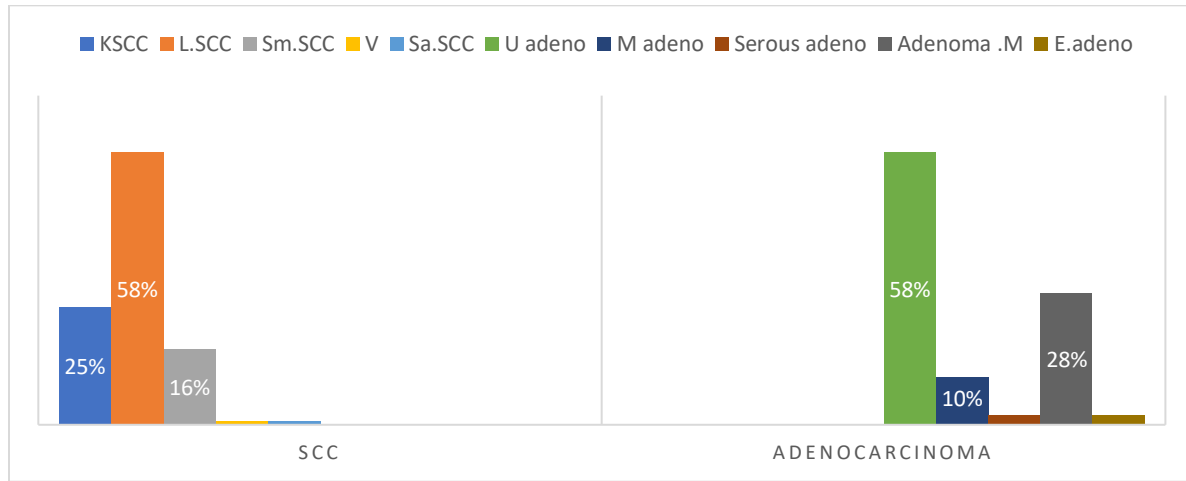
Age group	Squamous cell carcinoma	Adenocarcinoma	Total
< 37yrs	5	3	8
37-45yrs	34	10	44
46-53yrs	28	15	43
54-64yrs	38	8	46
65-75yrs	31	12	43
>75yrs	4	2	6
<b>Total</b>	<b>140</b>	<b>50</b>	<b>190</b>



**Figure 2. Description by age, major tumor category.**

The study found that the most often observed histological subtype of SCC in terms of microscopic morphology was large cell non-keratinizing SCC, which accounted for 82 out of 140 cases (58%). This was followed by keratinizing SCC, which accounted for 35 cases (25%), and tiny cell SCC, which accounted for 22 cases (16%). This investigation also identified two uncommon forms of SCC, namely the sarcomatoid type

and verrucous carcinoma. These two types accounted for a total of two cases. When examining cancer, the most often observed histologic pattern (morphology) was typical type adenocarcinoma, accounting for 28 out of 50 cases (58%). This was followed by adenoma malignum in 14 cases (28%) and mucinous adenocarcinoma in 5 cases (10%).



KSCC; keratinizing SCC, LSCC; large cell Non keratinizing, Sm.SCC; Small cell SCC, V; Verrucous carcinoma, sa.SCC; Sarcomatoid SCC, U.adeno; Usual type Adenocarcinoma, M.adeno; Mucinous Adenocarcinoma, Adenoma M; Adenoma Malignum, E.adeno; Endometrioid type Adenocarcinoma.

**Figure 3. Summarize the distribution by tumor category the morphologic subtype(histology)**

The average tumor size at initial diagnosis, together with the standard deviation, was  $2 \pm 1$ cm, ranging from a minimum size of 0.7cm to a maximum size of 6cm. The most common tumor sizes were less than 1cm, followed by the tumor size group of 2 to 2.5cm, then 3.1 to 3.5cm, and the least common were sizes more than 3.5cm. These sizes accounted for 54 out of 190 cases (28%), 52 cases (27%), 28 cases (15%), and 24 cases (12%) respectively. The majority of squamous cell carcinomas (SCC) in this study were found to have a tumor size between 2 and 2.5cm. On the other hand, most adenocarcinomas were less than 1cm, accounting for 41 out of 140 cases (29%) and

16 out of 50 cases (32%) respectively. In this study, the majority of cervical cancer cases were classified as grade II, followed by grade I. Specifically, grade II accounted for 103 out of 190 cases (54%), while grade I accounted for 63 out of 190 cases (33%). Based on the FIGO staging system from The International Federation of Gynecology and Obstetrics, the majority of cases were classified as Stage 1, but a small number of instances were classified as Stage 2, 3, and 4. Specifically, 171 out of 190 cases (90%) were in Stage 1, 11 cases (0.6%) were in Stage 2, 5 cases (0.3%) were in Stage 3, and 3 cases (0.2%) were in Stage 4.

**Table 3. Distribution by tumor size, major tumor category**

Tumor size	Squamous cell carcinoma	Adenocarcinoma	Total
<1cm	38	16	54
1_2cm	12	7	19
2_2.5cm	41	11	52
2.6_3cm	10	3	13
3.1-3.5cm	19	9	28
>3.5cm	20	4	24
Total	140	50	190



Table 4. Distribution by tumor size, grading and staging

Tumor size group	Grade 1	Grade II	Grade III	Total	Total
< 1cm	23	25	6	54	
1_2cm	5	12	2	19	
2.1_2.5cm	18	25	9	52	
2.6_3cm	6	7	0	13	
3.1_3.5cm	9	18	1	28	
>3.5cm	2	16	6	24	
Total	63	103	24	190	
Staging	Stage 1	Stage 2	Stage 3	Stage 4	Total
< 1cm	53	1	0	0	54
1_2cm	19	0	0	0	19
2.1_2.5cm	48	3	1	0	52
2.6-3cm	13	0	0	0	13
3.1-3.5	26	1	1	0	28
>3.5cm	12	6	3	3	24
Total	171	11	5	3	190

### Discussion

Cervical cancer remains a significant health issue, particularly in developing nations. It is also associated with severe consequences and tragic complications. However, by identifying the alarming indicators of cervical cancer, we can take preventive measures to mitigate its future implications. It is crucial to determine the histologic profile of the illness, as there are numerous histological variations of cervical cancer. Identifying and recording the different subtypes helps in providing precise treatment. Vaginal bleeding is the most frequent symptom observed in this study. However, urinary symptoms, which can indicate advanced diseases and metastasis, are less common, accounting for less than 10% of cases. This pattern is somewhat similar to that observed in North America, where vaginal bleeding is the primary symptom in all gynecologic malignancies [8]. The most prevalent tumor group, accounting

for 74% of cases, is Squamous Cell Carcinoma (SCC). This trend is also observed in developing countries, such as India [9]. However, the situation is distinct in the United States, where reproductive-aged White women have the highest occurrence of cervical adenocarcinoma relative to other age groups [10]. They employed diverse methodologies. The predominant histologic variants of cervical SCC in this study are large cell non-keratinizing, keratinizing SCC, and small cell SCC, which together make up 99% of the morphologic subtypes of SCC. The remaining cases are rare variants, with one case showing sarcomatoid differentiation SCC. This finding is consistent with a similar case reported in another country, where sarcomatoid differentiation was found to be associated with HPV33[11]. Additionally, there is a documented instance of verrucous carcinoma, which was previously reported as a case study in women with vaginal prolapse and in another case involving women with a history



of carcinoma in situ [12,13]. The majority of cases exhibit moderate differentiation (grade II), which is consistent with the findings published by Praiss, et al. [14]. Overall, carcinoma of the Uterine Cervix remains prevalent in the North Kordofan area. The most common histologic type observed is large cell non-keratinizing squamous cell carcinoma (SCC). It is recommended to implement strategies for early diagnosis and screening programs, since it is widely recognized that this cancer can be prevented in its premalignant stage.

### Conflict of interest

The author declares no conflict of interest

### Acknowledgement

The author would like to thank the histopathologists for their cooperation and collaboration.

### References

- 1\_ WHO 2024. Accessed at 12 June, 12 am, Available at [https://www.who.int/news-room/fact-sheets/detail/cervical-cancer?gad\\_source=1&gclid=EAIaIQobChMIvOBleSahgMVraODBx0yaAvUEAAAYASAAEgJ7-vD\\_BwE](https://www.who.int/news-room/fact-sheets/detail/cervical-cancer?gad_source=1&gclid=EAIaIQobChMIvOBleSahgMVraODBx0yaAvUEAAAYASAAEgJ7-vD_BwE)
- 2-Nicholas A Titiloye, Isaac Okai and Babatunde Muduyemi .Histopathological Features of Cervical Cancer in a Tertiary Hospital in Kumasi Ghana: A 9 Year Retrospective Study Vol. 7 No. 1 (2020) doi.org/10.4314/jmbs.v7il.3
- 3- Wang, M, Huang K, Wong M.C.S. *et al.* Global Cervical Cancer Incidence by Histological Subtype and Implications for Screening Methods. *J Epidemiol Glob Health* 14, 94-101 (2024). <https://doi.org/10.1007/s44197-023-00172-7>
- 4- Chelimo C, Wouldes TA, Cameron LD, Elwood JM. Risk factors for and prevention of

human papillomaviruses (HPV), genital warts and cervical cancer. *J Infect.* 2013 Mar;66(3):207-17. doi: 10.1016/j.jinf.2012.10.024. Epub 2012 Oct 26.

5- Cuzick J, Sasieni P, Davies P, Adams J, Normand C, Frater A, van Ballegooijen M, van den Akker-van Marle E. A systematic review of the role of human papilloma virus (HPV) testing within a cervical screening programme: summary and conclusions. *Br J Cancer.* 2015 Sep;83(5):561-5.

6 -Eze JN, Emeka-Irem EN, Edegebe FO. A Six-Year Study of the Clinical Presentation of Cervical Cancer and the Management Challenges Encountered at a State Teaching Hospital in Southeast Nigeria. *Clinical Medicine Insights: Oncology.* 2013;7. doi:10.4137/CMO.S12017

7- Jadhav A, Sanklecha V, Natekar A, Mahra R. Histopathological Study of Spectrum of Lesions of Uterine Cervix. *J Midlife Health.* 2023 Apr-Jun;14(2):112-116. doi: 10.4103/jmh.jmh\_28\_23. Epub 2023 Sep 18. PMID: 38029029; PMCI.

8-Hutchcraft ML, Miller RW. Bleeding from Gynecologic Malignancies. *Obstet Gynecol Clin North Am.* 2022 Sep;49(3):607-622. doi: 10.1016/j.ogc.2022.02.022. PMID: 36122988.

9\_Sathiyamurthy k , Waheeda S, Sangeetha N Histopathological study of cervical lesions in a tertiary health care centre in south India. doi.org/.18231/j.ijpo.2021.093

10 -Liao C, Furey K, Richardson M, *et al.* Rising incidence of cervical adenocarcinoma in the United States – who is most at risk? *International Journal of Gynecologic Cancer* 2020;30:A61.

11\_ Hrudka J, Rosová B, Halaška MJ. Squamous cell carcinoma with sarcomatoid differentiation or carcinosarcoma of the





uterine cervix associated with HPV33 infection: report of a rare case. *Diagn Pathol.* 2020 Feb 8;15(1):12. doi: 10.1186/s13000-020-00934-y. PMID: 32035484; PMCID: PMC7007670.

12\_Dane B, Dane C, Erginbas M, Baran S, Cetin A. Verrucous carcinoma of the cervix in a case with uterine prolapse. *Ann Diagn Pathol.* 2009 Oct;13(5):344-6. doi: 10.1016/j.anndiagpath.2009.02.005.

13\_Chen DC, Yu MH, Yu CP, Liu JY. Verrucous carcinoma of the uterine cervix. *Zhonghua Yi*

Xue Za Zhi (Taipei). 2000 Oct;63(10):765-9. PMID: 11076434.

14\_Praiss AM, Allison D, Tessier-Cloutier B, Flynn J, Iasonos A, Hoang L. Extensive versus focal lymphovascular invasion in squamous cell carcinoma of the cervix: A comprehensive international, multicenter, retrospective clinicopathologic study. *Gynecol Oncol.* 2023 Sep; 176:147-154. Doi: 10.1016/j.ygyno.2023.07.011.